



PATIENT

Dodger Rouf

SPECIES

Canine

BREED

Mix

SEX

MN

AGE

13y

WEIGHT

10.8lbs

INTERPRETED BY

Maggie Machen
Lamy, DVM, DACVIM
(Cardiology)

IMAGING PERFORMED BY

Tom McNeill, DVM

HOSPITAL NAME

Brook-Falls VH

REFERRING VET

Dr. Bloss

INVOICE

25792

DATE

8/15/22

PRESENTING CLINICAL SIGNS

History: Patient presented for a dental today. Exam revealed a more significant murmur ausculted. Abnormal PE/Chem/CBC/UA Results: Grade 3/6 murmur, previously 1/6. Thoracic radiographs revealed increase in VHS from 9.5 to 10.5/11 today. Bloodwork performed about 4 months ago was unremarkable.

RADIOGRAPHIC FINDINGS *NOTE: Images submitted for supplemental cardiac information only. Normal cardiac silhouette. No obvious evidence of CHF.

ELECTROCARDIOGRAPHIC FINDINGS *Note: Single lead ECGs are evaluated as a rhythm strip. Morphology/MEA cannot be definitively commented on.

A single lead ECG is available; 25mm/s, 10mm/mV. The average heart rate is 110bpm (range 100-125bpm). The rhythm is sinus in origin, with a p for every QRS complex and vice versa. The P and QRS morphologies are positive. No ectopic beats, pauses or other dysrhythmias observed. ECG diagnosis: Normal sinus rhythm with respiratory variation.

ECHOCARDIOGRAM FINDINGS

2D, m-mode, color flow and doppler imaging is available. Mild diffuse thickening of mitral valve leaflets with mild prolapse into the left atrial lumen. Mild eccentric mitral regurgitation with no left atrial dilation. Normal LV diameter with adequate myocardial function. The tricuspid valve appears normal with no tricuspid regurgitation. Normal right atrial and ventricular diameter and morphology indicating no overt evidence of pulmonary arterial hypertension. The pulmonic and aortic valves are normal in morphology and mobility. Normal pulmonic and aortic outflow velocities with laminar flow. Trace aortic and no pulmonic insufficiency. No pericardial or pleural effusion noted. No obvious cardiac masses.

CARDIAC CHART

CANINE CARDIAC PARAMETERS	MR VMAX (m/s)	TR VMAX (m/s)	LA/AO (Boon method)	LA/AO (Heart Base; Swe)	FS (%)	EF (%)	EPSS (cm)
NORMAL PARAMETER	4.5-5.5	<2.7	1.3	<1.6	28-40	40-100	<0.6
PATIENT			NM	1.3	41	74	0.12
CANINE CARDIAC PARAMETERS	HR (BPM)	AV VMAX (m/s)	PV MAX (m/s)	BODY WEIGHT (kg)	LA 2D short axis Base view (cm)	LVIDd Avg; 2D and m-mode short axis (cm)	LVIDs Avg; 2D and m-mode short axis (cm)
NORMAL PARAMETER	50-100	0.7-1.7	0.7-1.6	BELOW	BELOW	BELOW	BELOW
PATIENT	100	1.3	0.75	5	2.0	2.3	1.3
*Normal chamber parameters expressed as a mean value (SD)				3	1.27 (5.3)	2.46 (2.46)	1.36 (5.5)
BODY WEIGHT DEPENDENT PARAMETERS <i>*Note: All measurements based upon multi-modal images and methods. An average value is reported.</i>				5	1.40 (4.5)	2.74 (5.2)	1.60 (4.7)
				10	1.50 (3.8)	3.27 (3.5)	2.06 (3.1)
				15	1.83 (2.0)	3.71 (2.4)	2.43 (2.1)
				20	2.02 (1.9)	4.14 (2.2)	2.80 (2.0)
				25	2.18 (2.4)	4.48 (2.9)	3.10 (2.5)
				30	2.33 (3.3)	4.83 (3.9)	3.39 (3.4)
				35	2.48 (4.3)	5.17 (5.0)	3.69 (4.5)
Adapted from June Boon, Veterinary Echocardiography, 1998 Rishniw M and Hollis NE, J Vet Intern Med 2000; 14:429-435				40	2.62 (5.2)	5.48 (6.1)	3.96 (5.4)



PATIENT

Hansson et al, Vet Rad and Ultrasound 2002	50	2.88 (7.1)	6.07 (8.3)	4.46 (7.4)
Bonagura et al. Echocardiography: principles of interpretation, Vet Clin North Am. 15:1177-1805				

Dodger Rouf

SPECIES

Canine

BREED

Mix

SEX

MN

AGE

13y

WEIGHT

10.8lbs

INTERPRETED BY

Maggie Machen Lamy, DVM, DACVIM (Cardiology)

IMAGING PERFORMED BY

Tom McNeill, DVM

HOSPITAL NAME

Brook-Falls VH

REFERRING VET

Dr. Bloss

INVOICE

25792

DATE

8/15/22

INTERPRETATION OF THE FINDINGS & FURTHER RECOMMENDATIONS

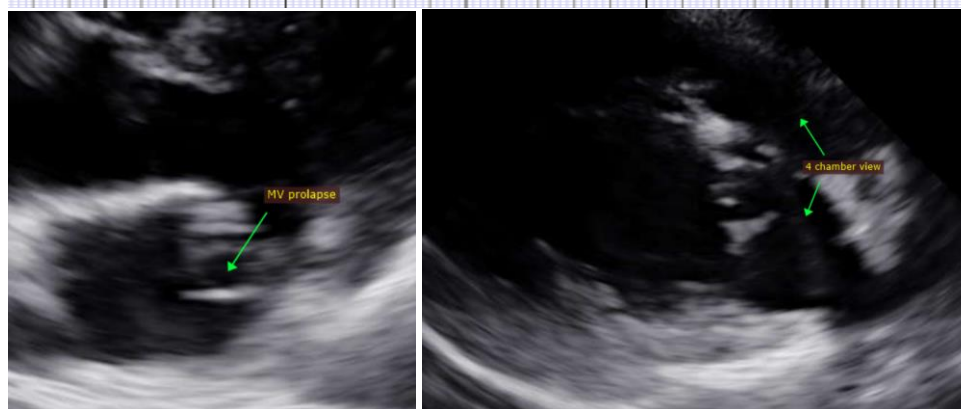
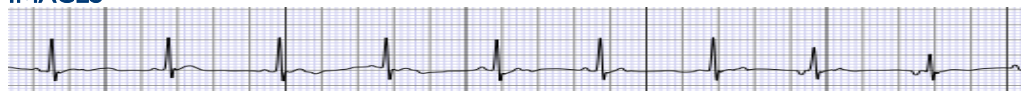
Chronic degenerative valve disease causing mild mitral and trace aortic regurgitation. Lack of significant left atrial enlargement indicates the current risk for complication is low. A baseline BP is recommended with aortic insufficiency. No concurrent issues such as systolic dysfunction or pulmonary hypertension are noted in this study. The ECG is unremarkable, with a normal sinus rhythm.

In an asymptomatic dog with no significant left atrial enlargement, no cardiac medications are clearly indicated. Assessment of progression in the future will help predict long term prognosis, which is highly variable at this stage (B1). Omega fatty acid supplementation and mild salt restriction may be of some long term benefit. Monitor for development of a cough, labored breathing, exercise intolerance or collapse episodes.

Anesthetic risk is considered mild if needed. Cardiac protective drug choices (opioid/benzodiazepine premedication, propofol or alfaxalone induction, isoflurane gas) are recommended. Pre-oxygenate for 5-10 minutes prior to induction. Monitor for arrhythmias, hypotension, and hypoxia both intra and post-operatively and intervene as necessary. Mild IV fluid restriction is recommended to avoid fluid overload. Avoid heart rate stimulating drugs such as atropine unless clinically indicated.

Recommend conservative monitoring with a recheck echocardiogram in 6-12 months, sooner if any development of clinical signs.

IMAGES



The information and recommendations provided are based on the images presented by the referring veterinarian. No evaluation can be communicated regarding pathology that was not visible in the image/video clips provided.

Thank you for this referral. If the clinical or image interpretation does not parallel your findings or if I can be of any further assistance please contact me.

Maggie Machen Lamy, DVM



PATIENT

Diplomate of the American College of Veterinary Internal Medicine (Cardiology)
info@sonopath.com

Dodger Rouf

SPECIES

Canine

BREED

Mix

SEX

MN

AGE

13y

WEIGHT

10.8lbs

INTERPRETED BY

Maggie Machen
Lamy, DVM, DACVIM
(Cardiology)

**IMAGING
PERFORMED BY**

Tom McNeill, DVM

HOSPITAL NAME

Brook-Falls VH

REFERRING VET

Dr. Bloss

INVOICE

25792

DATE

8/15/22